

## CASE REPORT

# SEIZURE CONTROL IN PATIENTS WITH ANTI-NMDAR ENCEPHALITIS : CASE SERIES

Indriyani Wijaya✉\*, Calcarina Fitriani Retno Wisudarti\*, Bowo Adiyanto\*, Farhan Ali Rahman\*

### Article Info :

Submitted :

03-01-2023

Accepted :

19-02-2024

Published :

30-04-2024

[https://doi.org/10.20961/  
sojaV4i1.69732](https://doi.org/10.20961/sojaV4i1.69732)

Authors' affiliations :

\*Faculty of Medicine,  
Public Health, and Nursing,  
Universitas Gadjah Mada,  
Yogyakarta, Indonesia

✉Correspondence:

[saphena\\_parva@yahoo.  
com](mailto:saphena_parva@yahoo.com)

### ABSTRACT

**Background:** Anti N-methyl-D-aspartate Receptor (anti-NMDAR) encephalitis is a rare, yet has had increasing number of cases. Patients often require airway protection, mechanical ventilation and intensive care because the patients' complex symptoms accompanied by seizures that are difficult to control. Here, we present two related case reports that discuss intensive care management and focus on the administered sedation/anesthesia methods and their outcomes.

**Case illustration:** Male patients, 19 and 21 years old, presented with neuropsychiatric symptoms, seizures, dyskinesia. Both require airway protection and mechanical ventilation as well as Intensive Care Unit (ICU) care. Radiodiagnostic head Computed Tomography (CT) scan and head Magnetic Resonance Imagng (MRI) showed no cerebral abnormalities. Cerebrospinal Fluid (CSF) examination showed positive NMDAR antibodies. First patient had failed to improve clinically even with multiple anti-convulsants, ketamine, dexmedetomidine, immunotherapy, and chemotherapy. Second patient clinically improved with benzodiazepine (midazolam) and propofol as anti-convulsants followed by plasma exchange immunotherapy. The two cases had different outcomes. The first case deceased from septic shock, while the second case was treated by outpatient procedure.

**Conclusion :** Our presented cases suggest that midazolam, propofol, dextemedetomidine, ketamine do not provide satisfying results for seizure control in patients with anti-NMDAR encephalitis, unless immunotherapy is carried out as early as possible and optimally.

**Keywords :** Anti-NMDAR encephalitis; Anti convulsant; Intensive care; Seizure.

## INTRODUCTION

Anti-NMDAR encephalitis was relatively reported in recent (12 years ago) and is a rare case, only 1.5 cases per million population per year and the first case in an adult patient at Sardjito General Hospital Yogyakarta. It is more common in women than men (4 : 1) and at a young age (median 21 years, range 1 – 85 years). Identification of NMDAR encephalitis is often difficult because 90% of cases have symptoms similar to those of primary psychiatric and behavioral disorders. Cognitive impairment, seizures, abnormal movements and coma without a clear cause are signs that can be found in this condition<sup>1</sup>.

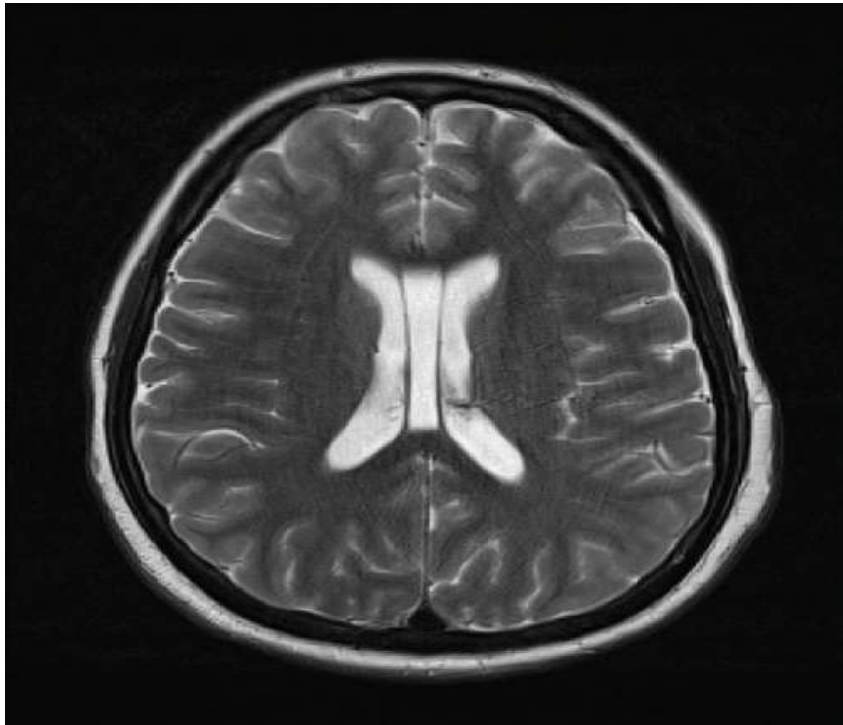
The role of the anesthesiologist, especially the intensivist, in the case of anti-NMDAR encephalitis is quite extensive, especially to provide supportive therapy while definitive therapy is carried out by a multidisciplinary team. In the acute phase, roles include : seizure treatment to secure the airway, breathing, and hemodynamics, use of anesthetic drugs for conditions that cannot be treated with traditional antiepileptic drugs, intensive care and use of intensive mechanical ventilation in the ICU, treatment of other complications caused by the primary disease, and performing perioperative management and anesthesia if the patient requires surgery. This case series aims to present various options of anesthetic drugs in controlling seizures in anti-NMDAR encephalitis.

## CASE ILLUSTRATION

### Case 1

Male, 21 years old, referred from peripheral hospital with complaints of headache, gibberish and confusion. Patient was diagnosed with acute psychosis, however in the second day of hospitalization, general seizure occurred. The patient then consulted to the neurology department. In the initial check, blood pressure was stable (systolic 100-110 mmHg, diastolic 70-85 mmHg), tachycardia with pulse rate of 100-120 beats per minute, respiratory rate of 16-20 times per minute, peripheral oxygen saturation was 97-98% with 10 liter per minute O<sub>2</sub> in Non-Rebreathing Mask (NRM).

Head MRI with contrast (Picture 1) and Head CT scan showed the result within normal limit. Laboratory test found anemia (Hb 8,9 g/dL), leukocytes and procalcitonin (leukocytes 9,67 10<sup>3</sup>/μL and procalcitonin 0,2 mcg/mL), electrolyte (natrium, potassium, chloride, calcium and magnesium) within normal limit, including from another laboratory checkings. Anti-rubella IgG antibody found results : 383 (positive), anti-CMV IgG result: 23.0 (positive), CMV avidity : 0.81 (significant), HIV rapid test : negative, non-reactive HbsAg, non-reactive total Anti ACV, thyroid function within normal limit, ANA IF test : negative.



Picture 1. Head MRI Case 1 show within normal limit

For seizure treatment, valproic acid and intermittent diazepam were initially used, but the seizure could not be ceased. Then, patient was consulted to anesthesiology and intensive therapy department to receive intermittent midazolam which also could not cease the seizure as well. Then, the patient was intubated and administrated with continuous propofol dose of 1mg/kg/hour; seizure could be relieved, but did not cease the upper arm and orofacial dyskinesia symptoms. Muscle relaxant was not administrated for it was deemed to obscure the symptoms, but could not prevent the breakthrough seizure. The patient was

given continuous ketamine in titrated doses up to a dose of 1 mg/kg/hour for 24 hours but the symptoms did not improve. Continuous dexmedetomidine in titrated doses up to a dose of 0.4 mg/kg/hour for 24 hours was also administrated if the patient's consciousness assessment was needed.

After almost a month since admitted to the hospital, anti-NMDAR checking on cerebrospinal fluid showed positive result. The patient underwent 3 plasma exchanges (41<sup>st</sup> day of hospitalization), and received antibiotic therapy, anticonvulsant therapy, acyclovir 800 mg/6 hours orally, levetiracetam 3000 mg loading, followed by 500 mg/8 hours

orally, phenytoin 100 mg /8 hours iv, and other supportive therapies. With 3-time plasma exchange (1 week interval per administration), the patient's clinical manifestations did not improve. Therapy was continued by administrating 1 time chemotherapy with Rituximab at a dose of 375 mg/m<sup>2</sup>. After chemotherapy, seizures and dyskinesia still occurred with varying frequency and duration every day. On the 76<sup>th</sup> day of hospitalization, the patient deceased from septic shock.

### Case 2

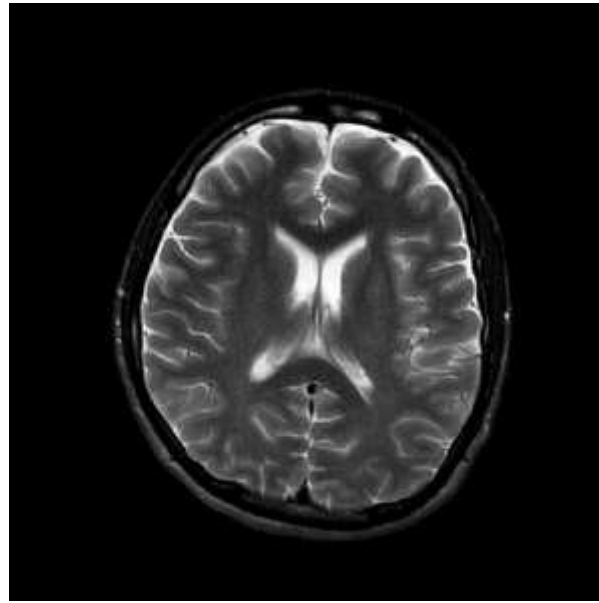
Male, 19 years old, was referred from a peripheral hospital with complaints of confusion and inadequate response in communicating. The family felt a change in the patient's behavior since 10 days before the hospital admission.

All comorbidities were denied, including the history of prohibited drugs and alcohol uses. In the admission day, the patient could not completely communicate and general seizures occurred with a duration that varies from 1 to 5 minutes occurred. Patient then consulted to neurology department and in the initial checking (during no seizure), blood pressure was 115/85 mmHg, pulse rate was 85 beats per minute, respiratory rate was 16-20 times per minute, peripheral oxygen saturation was 96% with 10 litre

per minute O<sub>2</sub> in Non-Rebreathing Mask (NRM).

Beside common seizure, focal seizure also occurred and there were involuntary movements in form of automatism movements on face (particularly mouth) and left hand. For seizure treatment, valproic acid and intermittent diazepam were used, however the seizure was getting worse on the 2<sup>nd</sup> day of hospitalization; the patient had respiratory distress and desaturation, then the patient was admitted to High Care Unit (HCU) and consulted to Anesthesiology and Intensive Care Department and decided to perform intubation and mechanical ventilation, as well as anticonvulsant escalation until continuous midazolam.

MRI with contrast (Picture 2) showed its results within normal limit. Laboratory test found leukocytosis of 15.1 10<sup>3</sup>/μL. Electrolyte (sodium, calcium, chloride, calcium, and magnesium) within normal limit, including in the other laboratory test result. Toxoplasma gondii, Rubella, Cytomegalovirus, Herpes Simplex Virus (TORCH) antibody resulted low to negative, negative HIV rapid test, non-reactive HbsAg, non-reactive total Anti-HVC, thyroid function within normal limit, negative ANA IF test.



Picture 2. Head MRI With Contrast Case

2 show within normal limit

Starting from the 8<sup>th</sup> day of hospitalization, plasma exchange therapy was done once everyday, with the total planned therapy of 5 times. In the 11<sup>th</sup> day of hospitalization, anti-NMDAR checking from cerebrospinal fluid showed positive result. Continuing the plasma exchange therapy up to 5 times (2 to 3-day interval per administration) was decided due to the clinical improvement showed (common seizure was reduced even automatism was still occurred and patient could do basic communication with others). Because the patient was predicted to still need long-term mechanical ventilation, Percutaneous Dilatational Tracheostomy (PDT) was decided to be done. Anticonvulsant while in HCU and ICU started from continuous midazolam, dose of 0.1 – 0.5 mg/kgBB/hour. Due to the seizure did not

cease, dose of propofol administration was additionally given for up to 1 mg/kgBB/hour. Midazolam and propofol combination could cease the seizure despite could not cease the automatism as well. Patient eventually admitted to ward after relieved from common and focal seizures for 5 days, no longer require mechanical ventilation, with minimum automatism symptoms. Patient could be released with nasogastric and tracheostomy tubes installed and the medication was continued by home care and outpatient procedure to neurology outpatient unit.

## DISCUSSION

NMDA receptor is one of ionotropic Glutamate Receptors (iGluRs). Seizure on anti-NMDAR encephalitis is a sign of CNS excitability due to the deteriorating NMDA receptor density on

cell surface which is caused by the bonding between B-cell response mediated antibody and NR1–NR2 heteromer sub-units of the NMDA receptor. It causes transmembrane movement disregulations of cations; synaptic transmission, synaptic plasticity,

and memory function, which clinically provide the descriptions for the occurrence of seizure, movement disorder, behavior irregularity, memory loss, psychosis, arrhythmias, and hypoventilation (mnemonic NMDAR, see picture 3)<sup>2</sup>.

<b>N</b> : Conscious disturbance, seizure, status epilepticus, psychosis
<b>MD</b> : Movement disorder, dyskinesia, automatism
<b>A</b> : Autonomic dysfunction
<b>R</b> : Hypoventilation

**Picture 3.** Clinical Manifestation of Encephalitis Anti-NMDAR <sup>3</sup>

In the first and second cases, the dominantly occurred clinical manifestation was seizure. Seizure often occurs on 50% of anti-NMDAR encephalitis cases (25% Status Epilepticus, 13.8% Refractory Status Epilepticus, and 10.2% Super Refractory Status Epilepticus). Seizures on the reported cases could be categorized into Super Refractory Status Epilepticus (SRSE), which is Refractory Status Epilepticus (RSE) that occurs for  $\geq 24$  hours. RSE itself is characterized by one of 2 seizure conditions, which are convulsive seizure, more than 60 minutes, could be continuous or intermittent seizure without return to baseline mental status; or an acute convulsive seizure that fails to respond to  $\geq 2$  anti-seizure medications (ASMs) including at least one non-benzodiazepine<sup>4</sup>. RSE condition is a life-threatening emergency condition that requires airway protection and ensurement of adequate ventilation as how the other

emergence treatments become the prioritized treatment to be done while ceasing the seizure as soon as possible.

Seizure and movement disorder/dyskinesia/automatism on anti-NMDAR encephalitis, which are parts of autoimmune process, oftenly require sedative and antiepileptic usages, or even long-term dose of anesthetic drugs that make these conditions become the treatment indication in the ICU, beside the needs of airway protection and mechanical ventilation. It is difficult to wean from mechanical ventilation, because patient with may require deep sedation due to seizure and movement disorder. Placement of tracheostomy sometime needed.

In the first and second cases, seizure ceasing was initially treated by diazepam and valproic acid, then replaced by up to continuous intermitten midazolam, however the seizure and automatism still occurred. The therapy

then was proceed by continuous propofol administration while providing definitive therapy (plasma exchange to chemotherapy) after a positive anti-NMDAR diagnosis was affirmed. Propofol, as either single agent or combined with midazolam, could not cease the seizure and automatism in the first case even a dose of 1 mg/kgBB/hour had been given, however the seizure could be ceased even the automatism still occurred. In the second case, these conditions are also possibly caused by the administration of earlier plasma exchange and complete dose series (5 times) that the overall patient's outcome could be repaired. In high dose, propofol caused hemodynamic decrease on both patients and assumed to increased the risk of Propofol Infusion Syndrome (PRIS) even it did not happen on the second case. In the first case, a continuous ketamine dose was titrated up to 1 mg/kg/hour for 24 hours. This seemed to contradict the mechanism of ketamine's action as an NMDA receptor antagonist, which is considered to be able to further reduce NMDA receptors that it exacerbated or triggered clinical manifestations. This theory is supported by several studies that do not recommend the use of ketamine in anti-NMDAR encephalitis, including when asymptomatic patients require anesthesia to facilitate surgery<sup>2,5</sup>.

On the other hand, there are reports claim that the use of ketamine may be benecial for unresponsive anti-NMDAR

encephalitis to the conventional anticonvulsant therapy. Ketamine with loading dose / initial doses followed by maintenance infusion (0.05 mg/kg/min infusion) could result in clinical and/or electrographic seizure cessation in less than 48 hours<sup>3</sup>. Another study reported that a combination of ketamine (initial dose 0.5 mg/kg followed by 0.5-1 mg/kg/hour, increased by 0.5 mg/kg/hour every 15-20 minutes to a maximum dose of 7.5 mg/kg/hour) with midazolam was responded by 73% of the study subjects with >50% burst suppression on the Electroencephalogram (EEG) and no breakthrough seizures occurred<sup>4</sup>.

The ketamine's action mechanism to suppress seizures in anti-NMDAR encephalitis remains unclear. Initial theory claimed that ketamine competes with anti-NMDAR antibodies for binding to the NMDA receptor so the receptor destruction could be prevented<sup>4</sup>. In the first case, a continuous dose of ketamine was titrated up to a dose of 1 mg/kg/hour for 24 hours, either as a single agent or in combination with midazolam, but the symptoms were neither improved nor worsen.

Continuous dose of Dexmedetomidine that was titrated up to 0,4 mcg/kg/hari had been given for 24 hours when the assessment of the patient's consciousness was required. In the first case, it was observed that dexmedetomidine did not reduce the frequency of seizures and did not achieve

the expected level of consciousness as well. The consciousness level did not improve with dexmedetomidine as did midazolam. Dexmedetomidine has been reported to be used for sedation in the ICU on patients with a history of anti-NMDAR encephalitis, secondary to ovarian teratoma patients who undergo laparoscopic ovariectomy under general anesthesia. It was reported that an adequate level of sedation was achieved at doses of 0.5–1.0 g/kg/hour and recovery from sedation was smooth and rapid without any deterioration of neurological or psychological symptoms<sup>5</sup>. However, in contrast to the first case, the patients in the study had only partial complex seizures that were controlled with a single dose of 5 mg midazolam iv. Dexmedetomidine itself has never been proven to control seizures in anti-NMDAR encephalitis because it does not have a direct effect on these receptors, so it is more often used as an anesthetic agent.

Definitive therapy for anti-NMDAR encephalitis by immunosuppression with steroids followed by immunoglobulins or plasma exchange, and removal of underlying neoplasm if any. Second line therapy is chemotherapy with rituximab or cyclophosphamide, or both<sup>6,7</sup>. Current best practice states that the administration of steroids in combination with Intravenous Immunoglobulin (IVIG) or plasma exchange should be initiated as early as possible in patients with severe

clinical symptoms. Second-line therapy is initiated 2-4 weeks after the completion of initial therapy or when the clinical suspicion is high and/or a clinically relevant antibody is present. Rituximab is considered if encephalitis is assumed to be caused by an antibody-mediated autoimmune process (such as anti-NMDAR encephalitis) and cyclophosphamide is considered if a cell-mediated process is detected<sup>7</sup>.

Supportive therapy that could be given to anti-NMDAR encephalitis is ketogenic diet. Ketogenic diet is also given in cases of seizures with other causes, either orally or parenterally. One study showed 10 of 14 patients on Ketogenic Diet had electrographic seizure resolution and 50% suppression starting on day 7 of the diet. The most common side effects are hypoglycemia and gastrointestinal symptoms such as emesis<sup>4</sup>. In both cases, the patient did not receive the ketogenic diet because diet preparations were not yet available in pharmacies and dietary modifications could not be made by the nutrition department.

The outcome of patients with anti-NMDAR encephalitis is varied. In general, prompt diagnosis and early immunotherapy give a good prognosis for adult patients,<sup>8</sup> whereas the need for intensive care is a good prognostic factor in some studies but also a poor prognostic factor in others. The timing of the start of plasma exchange is very different between the two cases, where the second case



undergo plasma exchange faster than the first case. Balu, *et al.* (2019) compiled an anti-NMDAR Encephalitis One-Year Functional Status (NEOS) score to predict

neurological function at 1 year after diagnosis (n = 382)<sup>9</sup>. (Table 2)

**Table 2.** Anti-NMDAR Encephalitis One-Year Functional Status (NEOS) score <sup>9</sup>

Factors	p	NEOS Score Point
Intensive Care Unit admission required	0.001	1
Lack of clinical improvement within 4 weeks of treatment	<0.001	1
No treatment within 4 weeks of symptom onset	0.002	1
Abnormal MRI	0.009	1
Elevated CSF white blood cell count > 20 cells/ $\mu$ L	0.019	1

NEOS score strongly associated with the probability of poor functional status at 1 year (p < 0.001)

- 3% for 0 or 1 point
- 69% for 4 or 5 points

The total NEOS score in the first case was 3 and in the second case it was 1, indicating different possible prognoses. In the second case, the patient was able to be discharged from the ICU and outpatient, but in the first case, the patient deceased on the 76<sup>th</sup> day of treatment due to septic shock. Susceptibility to infection is a serious concern in anti-NMDAR encephalitis patients who receive chemotherapy as in the first case.

## CONCLUSION

Our presented cases suggest that midazolam, propofol, dexmedetomidine, ketamine do not provide satisfying results for seizure control in patients with anti-NMDAR encephalitis, unless

immunotherapy is carried out as early as possible and optimally

## ABBREVIATION

NMDA : N-Methyl-D-Aspartate ; CNS : Central Nervous System; EEG : Electroencephalogram; iv : intravenous

## REFERENCE

1. Dalmau J, Armangué T, Planagumà J, Radosevic M, Mannara F, Leypoldt F, *et al.* An update on anti-NMDA receptor encephalitis for neurologists and psychiatrists: mechanisms and models. *The Lancet Neurology*. 2019 Nov;18(11):1045–57.
2. Al Ghamdi F, Uffman J, Kim S, Nafiu O, Tobias J. Anesthetic care for patients with anti-NMDA receptor encephalitis. *Saudi J Anaesth*. 2020;14(2):164.

3. Lin KL, Lin JJ. Neurocritical care for Anti-NMDA receptor encephalitis. *Biomedical Journal*. 2020 Jun;43(3):251–8.
4. Samanta D, Garrity L, Arya R. Refractory and Super-refractory Status Epilepticus. *Indian Pediatr*. 2020 Mar;57(3):239–53.
5. Yamanaka D, Kawano T, Tateiwa H, Iwata H, Locatelli FM, Yokoyama M. Successful management of dexmedetomidine for postoperative intensive care sedation in a patient with anti-NMDA receptor encephalitis: a case report and animal experiment. *SpringerPlus*. 2016 Dec;5(1):1380.
6. Haththotuwa HR, Malhas L, Jagadeeswaran A. Anti-NMDA Receptor Encephalitis: An Intensive Care Perspective. *Journal of the Intensive Care Society*. 2012 Apr 1;13(2):147–50.
7. Abboud H, Probasco JC, Irani S, Ances B, Benavides DR, Bradshaw M, *et al*. Autoimmune encephalitis: proposed best practice recommendations for diagnosis and acute management. *J Neurol Neurosurg Psychiatry*. 2021 Jul;92(7):757–68.
8. de Montmollin E, Demeret S, Brulé N, Conrad M, Dailier F, Lerolle N, *et al*. Anti- N -Methyl- D -Aspartate Receptor Encephalitis in Adult Patients Requiring Intensive Care. *Am J Respir Crit Care Med*. 2017 Feb 15;195(4):491–9.
9. Balu R, McCracken L, Lancaster E, Graus F, Dalmau J, Titulaer MJ. A score that predicts 1-year functional status in patients with anti-NMDA receptor encephalitis. *Neurology*. 2019 Jan 15;92(3):e244–52.