

Choledochal Cysts in Female Adult: Diagnostic Pitfall and Conservative Therapy for Bile Leak

Singgih Annas Fuadhi^{1,2*}, Agus Barmawi², Imam Sofii², Nurcahya Setyawan², Adeodatus Yuda Handaya²

*Corresponding author: annasfuadhi84@staff.uns.ac.id

Affiliation:

¹Department of Surgery, Faculty of Medicine, Universitas Sebelas Maret, Surakarta, Indonesia

²Digestive Division, Department of Surgery, Faculty of Medicine, Gadjah Mada University/RSUP Dr. Sardjito Hospital, Yogyakarta, Indonesia

Received: 20/03/2023
Accepted: 30/05/2023
Published: 31/08/2023

Creative Commons Attribution 4.0 International (CC BY 4.0)



ABSTRACT

Introduction: Choledochal cysts that are accompanied by obstructive jaundice are a rare case. These cysts can cause intrahepatic or extrahepatic ductal dilatation. Their diagnosis is difficult, particularly in adults. Proper management can prevent further complications.

Methods: A serial case report of a patient with a choledochal cyst.

Results: 2 female patients aged 21 years and 22 years have a painful and fixed lump in the upper right abdomen. The first patient also complained jaundice. Laboratory results showed an increase in total bilirubin and direct bilirubin. The second patient didn't complaint about jaundice or increased bilirubin, and she had a cholecystectomy when she was ten. The diagnosis was confirmed by a contrast abdominal CT scan, showing type 1A Todani choledochal cysts in both patients. Management of the first patient was cyst excision, cholecystectomy, and Roux n Y hepaticojejunostomy. In the second patient, adhesiolysis, cyst excision, and Roux n Y hepaticojejunostomy were performed. The second patient had no postoperative complications.

Conclusion: Choledochal cysts are a rare congenital condition in adulthood. In both cases, two patients were managed surgically. Bile leakage complications can be managed conservatively. Diagnostic and management of choledochal cysts must be correct to prevent pitfall and complications.

Keywords: choledochal cyst; complication; pitfall diagnosis

INTRODUCTION

Choledochal cyst is a rare condition. The incidence rate in America occurs is 0.007% (1:100,000 – 150,000), and in Asia is 0.1% (1:1000) of live births. A choledochal cyst is a congenital anomaly that causes congenital dilatation of any part of the biliary branch, intra or extra-hepatic². Choledochal cysts diagnosed in childhood is 75% and for an adult is 20%. This case is more common in women than men adults (3–4:1)³. Their diagnosis is difficult, particularly in adults. Diagnosis and management must be correct because in our second case the choledochal cyst was recurrent because only cholecystectomy was performed.

The clinical symptoms of choledochal cysts vary widely. Clinical symptoms that often occur are jaundice, right upper quadrant abdominal pain, colic pain, and the presence of a mass⁴. Choledochal cysts found in adulthood can be accompanied by complications such as cholangitis, stones in the biliary tract, rupture of cysts, secondary biliary cirrhosis, obstructive jaundice, and malignancy (cholangiocarcinoma)².

Choledochal cysts are classified into five types, according to Todani⁵. The Todani classification combines the Lej classification and the Caroli disease variation⁶. Ultrasonography (USG) is used as an initial examination of the choledochal cyst, followed by a computed tomography (CT) scan. CT scan can show the cyst type, its adhesions with surrounding organs, and staging if there is a possibility of malignancy that increases with age⁷. In first case report, a type 1A Todani choledochal cyst with obstructive jaundice and chronic abdominal pain was found in 21 years old female patient. In this case we got a bile leak complication which we treated conservatively by maintaining the drain for 1 week. And the therapy we did was successful without intervention or surgery. In the second patient, a 22-year-old woman, a choledochal cyst operation was performed. Previously, at the age of 10, a cholecystectomy was performed because of the same complaint. Most likely due to inappropriate diagnosis and management.

CASE PRESENTATION

Case 1

A 21-year-old female complained about a painful lump in the upper right abdomen accompanied by jaundice. These complaints have been felt since the age of twelve. The pain has been getting worse for two years before entering the hospital. The patient complains that her eyes become slightly yellow, accompanied by tea-colored urine and pale feces. The patient also complains about frequent nausea and vomiting. The physical examination revealed icteric sclera, a palpable mass with a diameter of 10 cm that fixed to the surrounding area, and pain in the upper right abdomen. Laboratory tests showed an increase in total bilirubin of 4.09 mg/dL, direct bilirubin of 3.65 mg/dL, and CEA of 7.76 ng/mL. CA 19-9 (18.29 U/mL) and CA 12-5 (9.11 U/mL) values were within the normal range. An abdominal CT scan found a lobulated cystic lesion on the distal to the proximal size of 10.27 x 8.09 x 8.03 cm accompanied by half widening of the left, and right intra-hepatic bile duct depicts a choledochal cyst. Cholecystitis was also found.

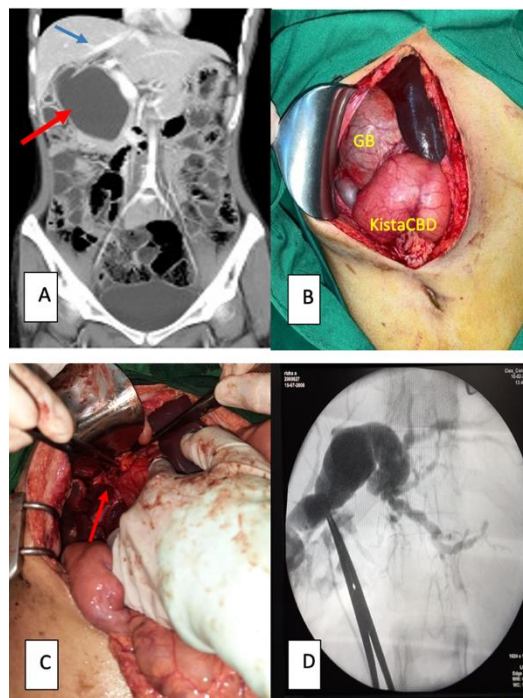


Figure 1. A. Choledochal cyst (red arrow) and dilatation of the right and left intrahepatic bile duct (blue arrow). B. Choledochal cyst (type 1A Todani) and bladder enlargement. C. Right and left hepatic ducts after cyst excision (red arrows). D. Intraoperative cholangiography after cyst excision.

At the time of the operation, a 15 x 11 x 9 cm choledochal cyst and enlargement of the vesica fellea were found. Findings during surgery conform to Todani's classification of type 1A. Then excision of the choledochal cyst was carried out until the confluence of the right and left hepatic ducts. The patient also underwent cholecystectomy, and then its material was sent to the anatomical pathology laboratory. After excision, intraoperative cholangiography was performed to evaluate the right and left intrahepatic bile duct (IHBD). Right and left IHBD got dilated. Reconstruction was performed with Roux n Y hepaticojejunostomy.

Anatomical pathology results concluded a choledochal cyst, and no malignancy was found. A cholesterol polyp was also found in the vesica fellea. After operation, drain products were estimated at 400-500 cc/24 hours a week. This complication was treated conservatively by retaining the drain and it was successful. Three weeks after surgery, total bilirubin (1.67 mg/dL), direct bilirubin (1.50 mg/dL), and indirect bilirubin (0.17 mg/dL) were examined and the bilirubin was reported to be decreasing. The patient did not complaint about pain in the upper right abdominal and yellow eyes anymore. Urination and defecation are normal.

Case 2

A 22-year-old female patient came with a chief complaint of a painful lump in the right upper abdomen. The patient had undergone cholecystectomy at the age of ten. The pain had been felt for three years before entering the hospital and was getting worse. She didn't complain jaundice. From the physical examination, a painful fixed around mass with a diameter of 6 cm was found in the upper right abdomen. From laboratory examination, total bilirubin was 0.47 mg/dL, and direct bilirubin was 0.20 mg/dL. The results of an abdominal CT scan showed a lobulated cystic lesion measuring 7.23 x 6.09 x 4.03 cm, which was described as a choledochal cyst.

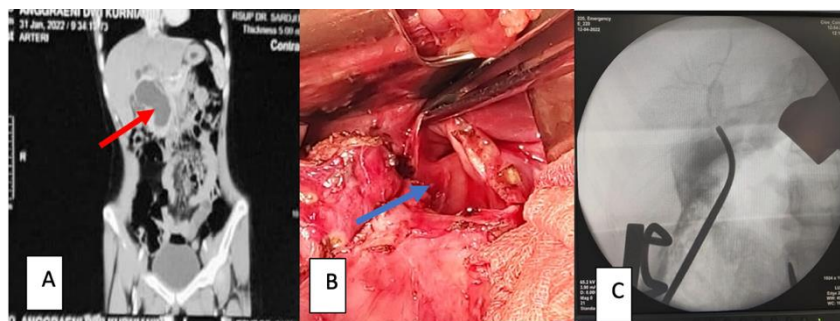


Figure 2. A. Choledochal cyst (red arrow), B. Right and left hepatic duct after cyst excision (blue arrow), C. Intraoperative cholangiography after cyst excision

During the operation, there were adhesions between the choledochal cyst, omentum, and transverse colon and then adhesiolysis was performed. A choledochal cyst measuring 6 x 6 x 4 cm conformed to Todani's classification of type 1A was found. Excision of the choledochal cyst was carried out until the right and left hepatic duct confluence. The specimen was sent to the anatomical pathology laboratory. After excision, intraoperative cholangiography was performed to evaluate the right and left intrahepatic bile duct (IHBD). Reconstruction was performed with Roux n Y hepaticojejunostomy. Anatomical pathology results concluded a choledochal cyst, and no malignancy was found. There were not any post-operative complications.

DISSCUSION

A choledochal cyst is a congenital abnormality of the bile duct. Most of these abnormalities are benign cysts with intrahepatic and/or extra-hepatic dilatation of the biliary tract⁴. This rare case was

first described by Vater and Ezler. Cyst formation can occur anywhere in the biliary tract, from the liver to the duodenum⁸.

In this case, type 1A Todani of the choledochal cyst was found, and according to the study of Hakimi and Machado, this type is the most common. The classification of choledochal cysts is divided according to the cyst's location, extension, and shape. The choledochal cyst was first classified by Alonso-Lej et al. in 1959. Later by Todani, the classification was associated with Caroli's disease⁹. Type I Todani (82% of cases) commonly presents with the dilated common bile duct. Type II (2-5% of cases) is a common bile duct diverticula. Type III (4% of cases) is also called a choledochal (intraduodenal) cyst. Type IV (10-20% of cases) is multiple cysts in the intrahepatic or extra-hepatic ducts. Type V (1% of cases) is characterized by single or numerous intrahepatic cysts (Caroli's disease)^{7,8}.

The etiology of choledochal duct cysts is still unclear. Two hypotheses have been explained. The first theory is due to partial obstruction of the biliary duct, which will increase the proximal pressure of the biliary duct, and dilation will occur starting from the extra-hepatic segment and then the intrahepatic duct. The second theory is based on Babbitt's theory which begins with the dilatation of the biliary ducts due to the reflux of pancreatic enzymes. The walls of the biliary ducts will weaken due to prolonged exposure to pancreatic enzymes. This reflux is due to abnormalities in the pancreaticobiliary duct relationship (Choledochalpancreatic or pancreatic-choledochal).^{6,8,10}

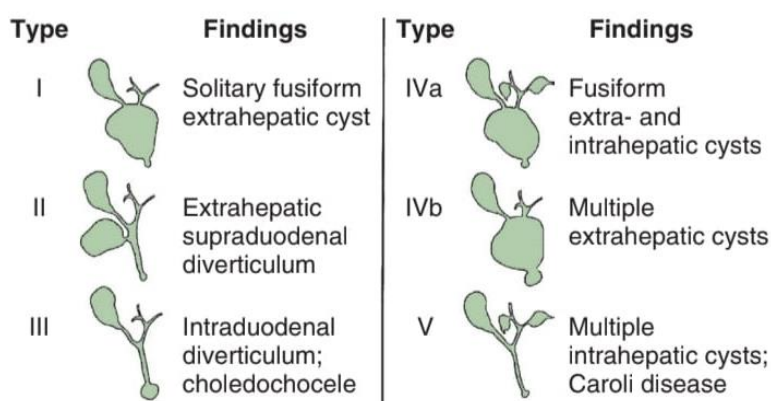


Figure 3. Classification of choledochal cysts according to Todani ¹⁴

Diagnosis of choledochal duct cysts in this patient was made based on physical examination, laboratory, and CT scan imaging. According to Hakimi, if there isn't a CT scan, an initial examination can be done with an ultrasound examination (USG), which is a cheap, non-invasive, but subjective modality. CT scan is accurate for determining size, location, and other abnormalities. Another additional examination is Endoscopic retrograde cholangiopancreatography (ERCP) which helps diagnose abnormalities in the distal duct. Magnetic cholangiopancreatography (MRCP) can replace ERCP, which is non-invasive and has high accuracy⁷.

Management of the choledochal cyst is highly dependent on the type of duct. The standard management for type IA Todani choledochal cysts is complete cyst excision and cholecystectomy followed by Roux n Y hepaticojejunostomy⁷. Type I and type IV choledochal cysts are the highest risk of becoming malignant, thus wide cyst excision, cholecystectomy, and Roux n Y hepaticojejunostomy are performed to reduce the risk¹¹. The operation can be done by laparoscopy or laparotomy. Common complications are bile leakage (7%), anastomotic strictures, intrahepatic cholelithiasis, pancreatitis, obstruction due to adhesions, and malignancy. Management of this patient is based on previous studies by Suleiman and Hakimi^{7,11,12}.

In the first patient, there was post-operative complication which is bile leakage with a product of 400-500 cc/24 hours for one week, and it was managed conservatively by maintaining the drain. After some evaluation, the drain product decreased, and eventually, we carried out an aff drain. From anatomical pathology results, there wasn't any malignancy in the choledochal cyst. Three weeks after surgery, bilirubin was examined, and there was a significant decrease in it.

In the second patient, the patient complained of pain in the right upper abdomen and felt a lump since he was 10 years old. The patient then underwent an abdominal ultrasonography and underwent a cholecystectomy laparotomy. Complaints are still felt by the patient. At the age of 22 years the patient was re-examined and underwent a CT scan of the abdomen and was diagnosed with a choledochal cyst. In this case highlights the difficulties involved in making a correct diagnosis and the operative treatment for a choledochal cyst.

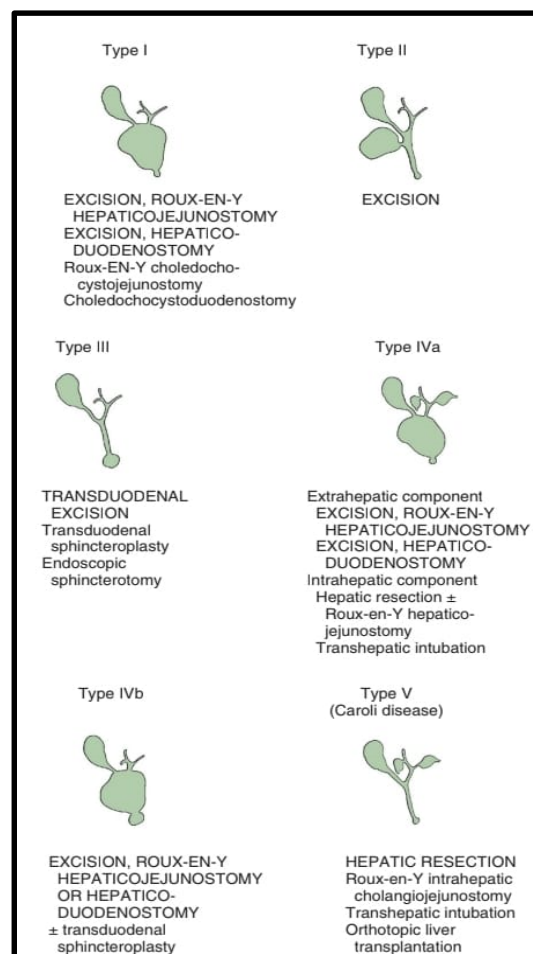


Figure 4. Surgical option for choledochal cysts ¹⁴

CONCLUSION

Choledochal cyst is a rare congenital condition in adults. Excision of the cyst and reconstruction by hepatojejunostomy is the standard therapy. The most common complication is bile leakage. By maintaining the drain, the leakage can be handled. Diagnostic and management of choledochal cysts must be correct to prevent pitfall and complications.

CONFLICT OF INTEREST

No potential conflict of interest relevant to this article was reported.

ACKNOWLEDGEMENTS

We thank to the surgical team and nurses who are involved in the excellent patient care.

REFERENCE

1. Saleh M.A., Vozzo C., Chahal P. EUS diagnosis of asymptomatic type III choledochal cyst. *VideoGIE* 2021; 6(2):98-100.
2. Albuquerque V.C.M.L., Macedo F.P.D., Costa K.G., Nunes Z.R.S., Junior R.A.S. Choledochal cyst- unusual presentation in the adult phase: Case report. *International Journal of Surgery Case Reports* 2020; 70:33-36. <https://doi.org/10.1016/j.ijscr.2020.03.014>
3. Lira a.K.M., Soto A.J.M., Frigerio P. Choledochal cyst Todani IA case report. *International Journal of Surgery Case Reports* 2016; 28:293-295. <http://dx.doi.org/10.1016/j.ijscr.2016.10.005>
4. Tsai P.H., Yen Y.C., Chou Y.H., Lin C.H., Bai Y.L., et all. Type I choledochal cyst complicated with acute hemorrhagic pancreatitis: A case report. *Journal of Medical Ultrasound* 2017; 25:235-239. <https://doi.org/10.1016/j.jmu.2017.09.003>
5. Pastor P., Ocana J., Gonzalez A., Nunez J., Garcia A., et all. Choledochal cysts surgical management: Retrospective and historical comparative analysis. *Cirugia Espanola*. 2022; 100(1):39-45.
6. Budipramana V. S. dan Saraswati P.A. Type IV choledochal cyst: A case report. *International Journal of Surgery Case Reports* 2020; 68:111-114. <https://doi.org/10.1016/j.ijscr.2020.02.033>
7. Hakimi T., Esmat H.A., Karimi R. Choledochal cyst: A challenging diagnostic and therapeutic entity in low-source settings. *International Journal of Surgery Case Reports* 2022; 90:1-4. <https://doi.org/10.1016/j.ijscr.2021.106729>
8. Machado N.O., Chopra P.J., Al-Zadjali A., Younas S. Choledochal cyst in adults: Ethiopathogenesis, presentation, Management, and outcome-Case series and review. *Hindawi Publishing Corporation Gastroenterology research and Practice* 2015:602951. <http://dx.doi.org/10.1155/2015/602591>
9. Soreide K., Korner H., Havnen J., Soreide J.A. Bile duct cysts in adults. *British Journal of Surgery* 2004; 91:1538-1548. DOI: 10.1002/bjs.4815.
10. Sallahu F., Hasani A., Limani D., Shabani S., Beka F., et all. Choledochal cyst-Presentation and treatment in an adult. *Acta Inform Med* 2013; 2(2):138-139. doi: 10.5455/aim.2013.21.138-139.
11. Suleiman J.M., Msuya D., Philemon., Sadiq A., Amsi P., Lodhia J. A giant choledochal cyst: A case report from Tanzania. *International Journal of Surgery Case Reports* 2021; 81:105829. <https://doi.org/10.1016/j.ijscr.2021.105829>

12. Tedeschi M., Cunha A.S., Pittau G. Laparoscopic treatment of choledochal cysts in adults: case report with video and review literature. *Laparoscopic Surgery* 2020; 4:1-10.
<http://dx.doi.org/10.21037/ls.2020.03.09>
13. Nguyen H.V., Do D.H., Nguyen H.V., Vu T.H., Hong Q.Q. Treatment of complex complications after choledochal cyst resection by multiple minimal invasive therapies: A case report. *International Journal of Surgery Case Reports* 2020; 73:130-133.
<https://doi.org/10.1016/j.ijscr.2020.06.104>
14. Croome, K.P., Nagorney, D.M. Bile duct cysts in adults. In: Blumgart's Surgery of the liver, biliary tract, and pancreas 6th edition. Elsevier. 2017;46:752-64.