

Advancing Surgical Oncology: Short-Term Outcome of Laser-Assisted Pulmonary Metastasectomy: A Case Series

Mada Ilham Bawono^{1 2*}, Darmawan Ismail³

*Corresponding author : madailham.mi@gmail.com

Affiliation:

¹ General Practitioner,
RSU Dadi Keluarga
Purwokerto, Central Java,
Indonesia

² Faculty of Medicine,
Universitas Jenderal
Soedirman, Purwokerto,
Indonesia

³ Departement of
Cardiothoracic and Vascular
Surgery, Moewardi General
Hospital, Surakarta,
Indonesia

Received: 03/02/2026
Accepted: 31/03/2026
Published: 23/04/2026

Creative Commons Attribution 4.0
International (CC BY 4.0)



ABSTRACT

The new surgical method of laser-assisted pulmonary metastasectomy enables surgeons to perform exact lung tissue removal while they maintain the ability to operate on multiple metastatic tumors. This study describes our experience and short-term outcomes of laser-assisted pulmonary metastasectomy.

We present two patients who underwent laser-assisted pulmonary metastasectomy for pulmonary metastases. The first patient was a 19-year-old woman with a history of osteosarcoma, in whom asymptomatic pulmonary metastases were detected during routine surveillance. The second patient was a 50-year-old woman with a history of right-sided bronchoalveolar carcinoma who presented with chronic cough, while imaging tests showed suspected metastatic lesions in her left lung. The two patients received laser-assisted pulmonary metastasectomy which involved the removal of one to three metastatic nodules. Both patients had mild hemoptysis as their only postoperative symptom while they experienced no other major health issues. Short-term outcomes were favorable, with operative times ranging from 1-2 hours, blood loss of 30-50 mL, chest tube duration of 4-5 days and a length of stay of 4-6 days

This preliminary experience indicates the technical applicability of laser-assisted pulmonary metastasectomy for resecting pulmonary metastases. The initial results showed positive short-term results, but researchers needed to conduct larger prospective studies to determine how effectively and safely the technique performed against standard procedures.

Keywords: Lasers-Assisted Metastasectomy; Lung Metastasis; Short-Term

INTRODUCTION

Lung is the one of the most common places for metastases from various malignancy, in estimation there is 50% of malignancy will metastases to lung¹. Cancer patients that already have pulmonary metastases will have a significant decrease in their life compared to cancer patients that have no pulmonary metastases. Cancer patient that already have a pulmonary metastases will have a significantly worse prognosis, in example 5-year survival rate on breast cancer patient with pulmonary metastases will decrease from 96% to 21%, on colorectal cancer with pulmonary metastases will decrease 5-year survival rate from 91% to less than 10%^{1,2}.

The poor prognosis associated with pulmonary metastases is largely driven by the complex biological characteristics of metastatic tumor cells. The cells that achieve successful metastasis to new locations represent a specific group of cancer cells which developed through clonal selection to possess greater ability to invade and adapt and resist treatment than their original tumor cells³⁻⁵. Epithelial carcinoma cells start their metastasis process when they undergo epithelial-mesenchymal transition

(EMT) which enables them to lose their intercellular connections and develop new movement abilities. The cells transform into circulating tumor cells (CTCs) after leaving their original location to enter the bloodstream where they must endure extreme mechanical and metabolic challenges. The metastatic cells develop mesenchymal–epithelial transition (MET) after they reach distant organs like the lung which restores their ability to grow and establish secondary tumor colonies².

The formation of a pre-metastatic niche by primary tumors enables them to create distant organs as locations for tumor cell migration which operates independently of tumor cells' native ability to move². Tumor-derived exosomes and pro-inflammatory cytokines create systemic factors which modify the pulmonary microenvironment to support tumor cell establishment and survival. The establishment of metastatic colonies allows tumor cells to escape immune detection through various mechanisms which include their ability to attract immunosuppressive cells while they activate immune checkpoint pathways⁶.

Some patients with metastatic disease show aggressive disease progression through their presence of limited metastatic spread which doctors identify as oligometastatic state⁷. This transitional stage represents a potentially treatable condition in which aggressive local therapy may provide survival benefit. Several studies have demonstrated that pulmonary metastasectomy in carefully selected oligometastatic patients can improve overall survival⁸.

Thoracic surgical techniques have progressed to create multiple approaches for pulmonary metastasectomy which utilize mechanical staplers and electrocautery and advanced energy devices that include Ligasure and Ultracision⁹. The current research demonstrates that every method used in the study shows its own specific constraints for implementation. Electrocautery produces two problems which include creating nonuniform resection surfaces and generating surgical smoke. Mechanical staplers restrict their use to peripheral lesions which require extensive central nodule resections that result in loss of healthy lung parenchyma^{10–12}.

The new surgical method of laser-assisted pulmonary metastasectomy enables removal of multiple lung metastases from both lung outer regions and lung central regions while maintaining lung parenchyma⁹. Compared with conventional techniques, laser-assisted pulmonary metastasectomy may enable removal of numerous metastases during a single procedure with minimal tissue damage^{10,13}. Given that this technique remains relatively novel and clinical evidence continues to evolve, this case report aims to highlight the potential role of laser-assisted pulmonary metastasectomy in the management of complex pulmonary metastases.

CASE PRESENTATION

Case Presentation One

A 19-year-old woman was referred due to suspicion of pulmonary metastases based on MSCT findings. The patient reported no breathing difficulties and no coughing and no other symptoms. The patient had osteosarcoma affecting her left leg which required amputation as a treatment. The complete history of disease progression is described in Figure 1. The patient denied any family history of malignancy. The physical examination showed normal lung function while the left leg showed an amputation stump.

Radiological examination showed multiple bilateral pulmonary nodules, and the right subpleural nodule was nodular and of the subpleural pulmonary metastasis type. The patient had good preoperative status with a hemoglobin level of 13.7 g/dL.

The patient, having previously undergone a right-sided laser-assisted metastasectomy, was scheduled for a sequential procedure on the left lung. The surgical procedure used a lateral thoracotomy approach for its execution. We operated the 980-nm laser diode dual wavelength system in continuous mode at a power setting of 25 Watts. The system enabled exact tissue removal procedure with 5-mm

margin boundaries which we applied to each tumor. In this session, three solitary tumors were successfully resected (Figure 2.A) over an operative duration of 2 hours, with blood loss of 50 mL. The surgical procedure succeeded in closing the parenchyma through laser ablation which accomplished complete sealing of the lung surface. The surgical team performed an intraoperative air-leak test by using warm saline immersion, which showed no substantial bubbling from the resection beds. Histopathological examination subsequently confirmed the metastasis of giant cells–rich osteosarcoma with clear surgical margins.

The patient stayed in the hospital for four days after his surgery. The patient during his stay at the hospital reported two symptoms which included hemoptysis and minor pain at the surgical site that showed improvement every day. The laboratory test results indicated that the patient's hemoglobin level remained unchanged at 12.2 g/dL which showed the patient had no major blood loss during the surgical procedure. Arterial blood gas analysis showed mild respiratory acidosis with hypoxemia (pH 7.323, PCO₂ 44 mmHg, PO₂ 53.0 mmHg, O₂ saturation 87.7%). The patient's chest tube was removed on the last day of hospitalization, which was day 4.

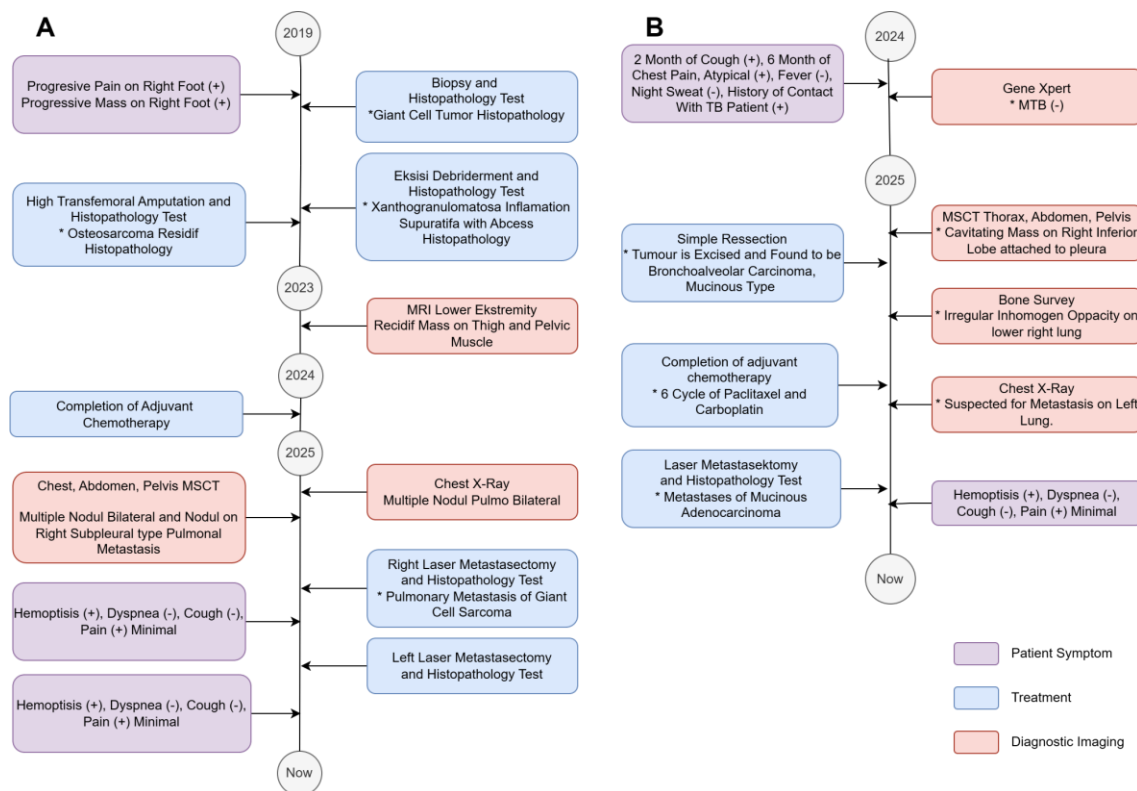


Figure 1. Progression of disease, (A) Case One, (B) Case Two

Case Presentation Two

A 50-year-old woman presented with complaints of recurrent cough that had not resolved for 2 months; the patient also frequently complained of pain in the left chest. The patient had a history of adenocarcinoma in the right lung and had undergone resection; the patient had also completed a chemotherapy program. Refer Figure 1 for detailed disease history of the patient. There were no findings on the lungs examination.

Radiological examination showed the possibility of metastasis from the right lung to the left lung. The patient had good baseline status with a hemoglobin level of 13.7 g/dL.

The procedure was performed through a lateral thoracotomy approach which used a dual-wavelength diode laser system that operated at 980 nanometers with continuous mode power output of

25 Watts. The configuration enabled the surgeons to remove the tissue while maintaining a 5-millimeter control distance from the surrounding lesion. The operation successfully removed one solitary tumor (Figure 2.B) within a 1-hour operative duration and a blood loss of 30 mL. The surgical team used specific laser ablation methods to close the resection bed because they needed to achieve both air and blood flow control. The surgical team conducted an intraoperative air-leak test to check the repair's integrity which used warm saline immersion and showed no remaining leaks. The following histopathological examination showed that mucinous adenocarcinoma had spread beyond surgical margins.

The patient needed to stay in the hospital for 6 days after his surgery. The patient during his hospital stay reported experiencing hemoptysis and showed only slight discomfort at the surgical area, which got better every day. The laboratory test results showed no major drop in the patient's hemoglobin level which measured 14.6 grams per deciliter thus proving that the patient experienced no major blood loss during the operation. The patient's chest tube was also able to be removed on day 5.

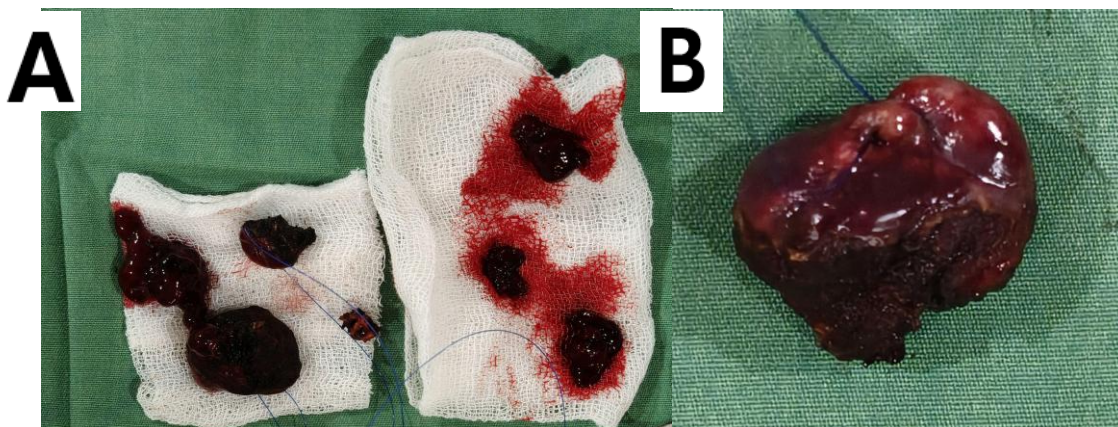


Figure 2. Resected Tumour (A) Case one, (B) Case two

DISCUSSION

The first two cases which we studied indicate that laser-assisted metastasectomy shows promise when applied in specialized thoracic surgical environments. Our study found that short-term perioperative outcomes in patients matched the results reported in previous studies which showed operative duration of 1 to 2 hours and estimated blood loss below 50 mL and chest tube duration of 4 to 5 days^{14,15}. These results likely reflect the laser's technical advantages; higher parenchymal preservation potentially accelerates recovery and reduces chest tube duration^{16,17}, while its simultaneous hemostatic effect likely accounts for the minimal bleeding and operative efficiency observed¹⁸. Regarding the length of stay, our observed duration (4–6 days) was slightly shorter than the median reported in the literature (7 days; range 4–24 days)¹⁴. This difference might be caused by variable metastatic burden (1–13 lesions) and surgical approach (VATS and Thoracotomy) in the study¹⁴.

Laser-assisted metastasectomy provides better benefits than traditional stapler-based wedge resections for certain medical conditions which require treatment of deep pulmonary metastases or multiple lung metastases⁹. The laser's precise capabilities enable doctors to remove specific areas of lung tissue while maintaining a higher amount of functioning lung material, which benefits patients who need multiple surgeries to treat their ongoing metastatic cancer and who have limited lung function¹⁶. The advantages of laser assisted metastasectomy procedure must be assessed together with its technical and systemic constraints. The histological margin assessment process becomes more

difficult because the laser treatment destroys and seals off tissue, which makes it harder to analyze¹⁹. The technology also cannot be used widely because it requires users to complete an extensive training program which needs specialized education and its equipment expenses are high.

The study results face inherent limitations which extend beyond the technical and systemic barriers that restrict the research process. The report has three limitations which include its small sample size of two participants and the missing control group and no information on the long-term outcome. The study shows that laser-assisted metastasectomy provides technical viability for parenchymal-sparing surgical procedures which doctors can use to treat specific patients who have pulmonary metastases. The research needs to conduct more extensive studies which will examine cancer outcomes over an extended period to better determine the method's effectiveness and safety and cost efficiency compared to standard surgical procedures.

CONCLUSION

This case report demonstrated technical feasibility of laser-assisted metastasectomy for pulmonary metastases in achieving tumor resection while preserving lung parenchyma. The procedure demonstrated acceptable short-term perioperative outcomes (operative time, blood loss, chest tube duration, and length of stay).

However, given the limitation of the study, these findings should be interpreted with caution and further studies with larger patient cohorts and longer follow-up are required to better evaluate the clinical outcomes and potential role of laser-assisted metastasectomy in the management of pulmonary metastases.

ACKNOWLEDGMENT

The authors would like to extend their sincere gratitude to the entire surgical and nursing teams at Moewardi General Hospital, Surakarta, for their exceptional collaboration, dedication, and support in managing the patients presented in this case series. We also thank the patients and their families for their trust and cooperation.

REFERENCES

1. Zullo L, Filippiadis D, Hendriks LEL, Portik D, Spicer JD, Wistuba II, et al. Lung metastases. *Nat Rev Dis Primer*. 2025 Aug 21;11(1):60. doi:10.1038/s41572-025-00642-1
2. Jamil A, Kasi A. Lung Metastasis [Internet]. Treasure Island (FL): StatPearls Publishing. Available from: <https://www.ncbi.nlm.nih.gov/books/NBK553111/>
3. Talmadge JE. Clonal Selection of Metastasis within the Life History of a Tumor. *Cancer Res*. 2007 Dec 15;67(24):11471–5. doi:10.1158/0008-5472.CAN-07-2496
4. Ramos A, Sadeghi S, Tabatabaeian H. Battling Chemoresistance in Cancer: Root Causes and Strategies to Uproot Them. *Int J Mol Sci*. 2021 Aug 31;22(17):9451. doi:10.3390/ijms22179451 PubMed PMID: 34502361; PubMed Central PMCID: PMC8430957.
5. Petrella F, Diotti C, Rimessi A, Spaggiari L. Pulmonary metastasectomy: an overview. *J Thorac Dis*. 2017 Oct;9(S12):S1291–8. doi:10.21037/jtd.2017.03.175
6. Salehi-Rad R, Dubinett SM. Understanding the mechanisms of immune-evasion by lung cancer in the context of chronic inflammation in emphysema. *J Thorac Dis*. 2019 Feb;11(2):382–5. doi:10.21037/jtd.2019.01.22 PubMed PMID: 30962980; PubMed Central PMCID: PMC6409254.

7. Izmailov T, Ryzhkin S, Borshchev G, Boichuk S. Oligometastatic Disease (OMD): The Classification and Practical Review of Prospective Trials. *Cancers*. 2023 Oct 31;15(21):5234. doi:10.3390/cancers15215234 PubMed PMID: 37958408; PubMed Central PMCID: PMC10648904.
8. Fernandez RAS, Lau RWH, Ho JYK, Yu PSY, Chow SCY, Wan IYP, et al. Evidence for surgical resections in oligometastatic lung cancer. *J Thorac Dis*. 2019 Apr;11(S7):S969–75. doi:10.21037/jtd.2019.04.09
9. Grapatsas K, Papaporfyriou A, Leivaditis V, Ehle B, Galanis M. Lung Metastatectomy: Can Laser-Assisted Surgery Make a Difference? *Curr Oncol Tor Ont*. 2022 Sep 26;29(10):6968–81. doi:10.3390/curroncol29100548 PubMed PMID: 36290825; PubMed Central PMCID: PMC9600252.
10. Kirschbaum A, Braun S, Rexin P, Bartsch DK, Seyfer P. Comparison of local tissue damage: monopolar cutter versus Nd:YAG laser for lung parenchyma resection. An experimental study. *Interact Cardiovasc Thorac Surg*. 2014 Jan 1;18(1):1–6. doi:10.1093/icvts/ivt419
11. Osei-Agyemang T, Palade E, Haderthauer J, Ploenes T, Yaneva V, Passlick B. Pulmonary Metastasectomy: An Analysis of Technical and Oncological Outcomes in 301 Patients with a Focus on Laser Resection. *Zentralblatt Für Chir - Z Für Allg Visz Thorax- Gefäßchirurgie*. 2013 Oct 22;138(S 01):S45–51. doi:10.1055/s-0033-1350873
12. Heaton TE, Davidoff AM. Surgical treatment of pulmonary metastases in pediatric solid tumors. *Semin Pediatr Surg*. 2016 Oct;25(5):311–7. doi:10.1053/j.sempedsurg.2016.09.001 PubMed PMID: 27955735; PubMed Central PMCID: PMC5462002.
13. Liu L, Zhang Y, Zhi X, Liu B. A retrospective comparative study of thulium laser and mechanical stapler in pulmonary wedge resection under thoracoscopy. *J Cancer Res Ther*. 2021 Dec;17(7):1696–701. doi:10.4103/jcrt.jcrt_682_21
14. Hassan M, Graeter T, Dietrich I, Kemna LJ, Passlick B, Schmid S. Surgical Morbidity and Lung Function Changes After Laser-Assisted Pulmonary Metastasectomy: A Prospective Bicentric Study. *Front Surg*. 2021 Jun 1;8:646269. doi:10.3389/fsurg.2021.646269
15. Meyer C, Bartsch D, Mirow N, Kirschbaum A. Video-Assisted Laser Resection of Lung Metastases—Feasibility of a New Surgical Technique. *Thorac Cardiovasc Surg*. 2017 Aug;65(05):382–6. doi:10.1055/s-0036-1597990
16. Chandarana K, Caruana EJ, Weaver H, Rathinam S, Nakas A. Laser pulmonary metastasectomy preserves parenchyma: a single-centre retrospective study from the United Kingdom. *Cardiothorac Surg*. 2022 Nov 29;30(1):27. doi:10.1186/s43057-022-00088-1
17. Schmid S, Le UT, Zeisel C, Haager B, Passlick B. Pulmonary metastasectomy in sarcoma—experiences with laser-assisted resection. *J Thorac Dis*. 2018 Jan;10(1):314–20. doi:10.21037/jtd.2017.12.06 PubMed PMID: 29600062; PubMed Central PMCID: PMC5863185.
18. Panagiotopoulos N, Patrini D, Lawrence D, Scarci M, Mitsos S. Pulmonary metastasectomy and laser-assisted resection. *J Thorac Dis*. 2018 Jun;10(Suppl 17):S1930–3. doi:10.21037/jtd.2018.05.08 PubMed PMID: 30023083; PubMed Central PMCID: PMC6036023.
19. Mammana M, Baldi M, Melan L, Dell’Amore A, Rea F. Laser-assisted lung metastasectomy: a systematic review. *Updat Surg*. 2023 Oct 1;75(7):1783–93. doi:10.1007/s13304-023-01564-x